

Bestanchuk E., Gozhenko A., Kashchenko O., Narbutova T., Berezovskyi O., Zakharova V. Cardiotoxic effect of bleomycin with a single administration in the experiment. *Journal of Education, Health and Sport*. 2021;11(10):242-251. eISSN 2391-8306. DOI <http://dx.doi.org/10.12775/JEHS.2021.11.10.022> <https://apcz.umk.pl/JEHS/article/view/JEHS.2021.11.10.022> <https://zenodo.org/record/5636149>

The journal has had 5 points in Ministry of Science and Higher Education parametric evaluation. § 8.2) and § 12.1.2) 22.02.2019.
© The Authors 2021;

This article is published with open access at Licensee Open Journal Systems of Nicolaus Copernicus University in Torun, Poland
Open Access. This article is distributed under the terms of the Creative Commons Attribution Noncommercial License which permits any noncommercial use, distribution, and reproduction in any medium, provided the original author(s) and source are credited. This is an open access article licensed under the terms of the Creative Commons Attribution Non commercial license Share alike. (<http://creativecommons.org/licenses/by-nc-sa/4.0/>) which permits unrestricted, non commercial use, distribution and reproduction in any medium, provided the work is properly cited.
The authors declare that there is no conflict of interests regarding the publication of this paper.

Received: 30.09.2021. Revised: 12.10.2021. Accepted: 29.10.2021.

Cardiotoxic effect of bleomycin with a single administration in the experiment

**E. Bestanchuk¹, A. Gozhenko², O. Kashchenko³, T. Narbutova³, O. Berezovskyi⁴,
V. Zakharova⁵**

¹Odessa Regional Oncological Dispensary, Odessa, Ukraine

**²Ukrainian Research Institute of Transport Medicine of the Ministry
of Health of Ukraine, Odessa, Ukraine**

³Odessa National Medical University, Odessa, Ukraine

⁴"ODREX" Medical Center, Odessa, Ukraine

⁵Amosov National Institute of Cardiovascular Surgery, Kiev, Ukraine

Abstract

The aim of the study was to evaluate the effect of a single injection of bleomycin on the heart

Material and methods. The study was conducted in the Research Institute of Transport Medicine during 2016-2021. The experimental model of the cardiotoxic effect of the bleomycin was performed using the medication "Bleocin" manufactured by Nippon Kayaku Co., Ltd. (Japan). According to the task, the study was performed on 10 mature rats of both sexes of the Wistar line with a body weight of 237 ± 20 g.

Rats were housed in standard vivarium conditions of Odessa National Medical University. Animals were divided into 2 groups: experimental group (n = 5) and control (n = 5). Bleomycin animals of the experimental group were obtained intraperitoneally at a dose of 0.5 IU / kg once. Withdrawal of animals from the experiment was performed on the 5th day of the experiment, followed by morphological and morphometric examination.

Statistical processing of the obtained data was performed by methods of variance, correlation and regression analysis using Statistica 14.0 software (TIBCO, USA)

Results. Single administration of bleomycin causes changes in macroscopic parameters (myocardial weight, visual changes) are minimal. The main changes at the microscopic level are represented by contractural degeneration with segmental and / or partial-lateral lysis, ie there is not total but partial myocardial damage.

Conclusion. A single injection of bleomycin can cause inflammatory-dystrophic changes of the myocardium.

Key words: cardiotoxicity; low dose; single dose; pathology; bleomycin; experimental study

Widespread use of various chemotherapy regimens in the treatment of patients with Hodgkin's lymphoma, testicular and ovarian cancer, skin cancer, lung cancer, thyroid cancer; malignant non-Hodgkin's lymphomas; reticulosarcomas; cancer of the penis and female external genitalia, cervical cancer makes it possible to increase the life expectancy of patients, improve its quality, thereby improving the prognosis. In most schemes with the above-described oncological pathology, the bleomycin is used [1-3]. Bleomycin is an antitumor antibiotic, which is an A2 fraction isolated from a culture of *Streptomyces verticillus*. Among the known side effects of bleomycin in the first place, there are toxic effects on lung tissue with the development of pulmonary fibrosis, pleurisy with pain, increasing respiratory failure; rarely - toxic effects on blood vessels, including cerebral arteritis, stroke, myocardial infarction, thrombotic microangiopathy, Raynaud's syndrome [1, 4]. At the same time, not much is known about the toxic effect on the myocardium, especially with intravenous administration of the drug.

The pathophysiological mechanism of acute chest pain described during bleomycin infusion remains unclear. A possible explanation may be serous inflammation, which manifests as acute pleuropericarditis or as part of a more generalized mucocutaneous toxicity common to bleomycin therapy. The vascular etiology of pain should also be considered, as other pulmonary vascular diseases, such as pulmonary hypertension and pulmonary embolism, can cause both substernal and pleurisy chest pain even in the absence of infarction [5]. Unfortunately, the morphological substrate of the cardiotoxic effect of bleomycin remains unclear.

The aim of the study was to evaluate the effect of a single injection of bleomycin on the heart

The study was conducted in the Research Institute of Transport Medicine during 2016-2021

The experimental model of the cardiotoxic effect of the bleomycin was performed using the medication "Bleocin" manufactured by Nippon Kayaku Co., Ltd. (Japan). According to the task, the study was performed on 10 mature rats of both sexes of the Wistar line with a body weight of 237 ± 20 g.

Rats were housed in standard vivarium conditions of Odessa National Medical University. Animals were divided into 2 groups: experimental group (n = 5) and control (n = 5). Bleomycin animals of the experimental group were obtained intraperitoneally at a dose of 0.5 IU / kg once. Withdrawal of animals from the experiment was performed on the 5th day of the experiment, followed by morphological and morphometric examination.

The material after weighing and morphometry was fixed with a neutral 10% formalin solution and poured into paraffin. Histological sections were stained with hematoxylin-eosin, MSB, Van Gizon. Performed light microscopy.

Assessment of the cardiotoxic effect of bleomycin was performed on clinical grounds: observation of experimental animals, standard morphological examination (evaluation of macrodrugs, morphological examination - light microscopy of histological sections stained with hematoxylin-eosin, MSB, Van Gizon) [6].

During the experimental stage, the research was guided by the provisions of the "European Convention for the protection of vertebrate animals used for experimental and other purposes" (Strasbourg, 1985), as well as the Law of Ukraine № 3446-IV of 21.02.2006, Kyiv "On protection animals from cruel treatment "[7].

Statistical processing of the obtained data was performed by methods of variance, correlation and regression analysis using Statistica 14.0 software (TIBCO, USA) [8]. The null hypothesis was accepted at $p > 0,05$.

Results

In animals of the control group, the weight of the heart was 1.19 ± 0.25 g. Macroscopic changes on examination were not detected. The myocardium was formed by multidirectional layers of muscle fibers; cardiomyocytes (CMC) are connected by insertion disks and signs of branching. Each fiber is surrounded by thin layers of loose connective tissue that contains capillaries. Externally, the heart is covered with epicardium. The

subepicardial layer of CMC, which has a circular direction, was well visualized. The endocardium was represented by the endothelium and a thin layer of loose connective tissue (Fig. 1, 2)

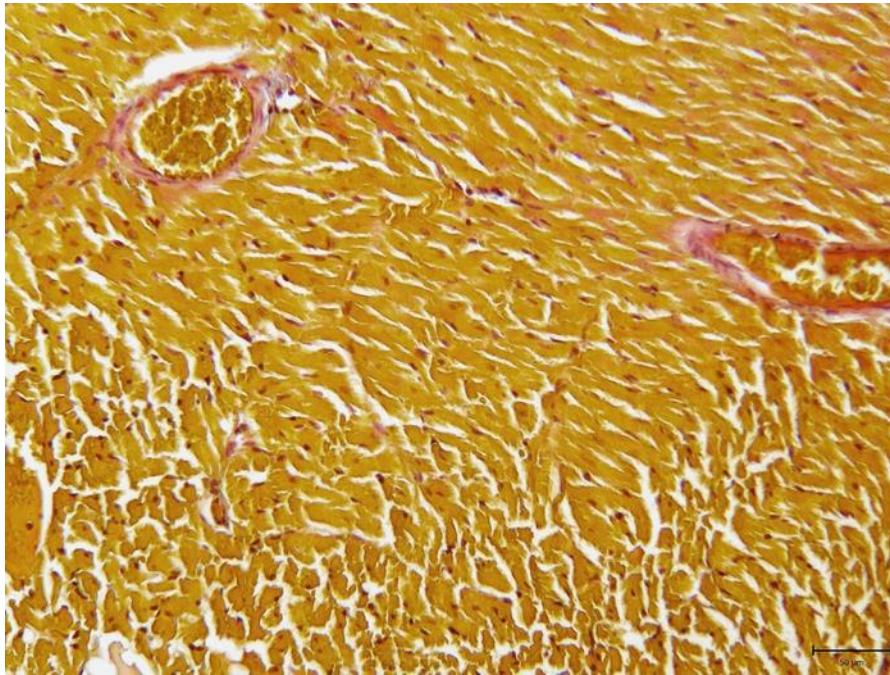


Fig. 1. Fragment of the rat myocardium of the control group. Single contractural changes. The walls of the artery are thin, without edema. Coloring MSB X200.

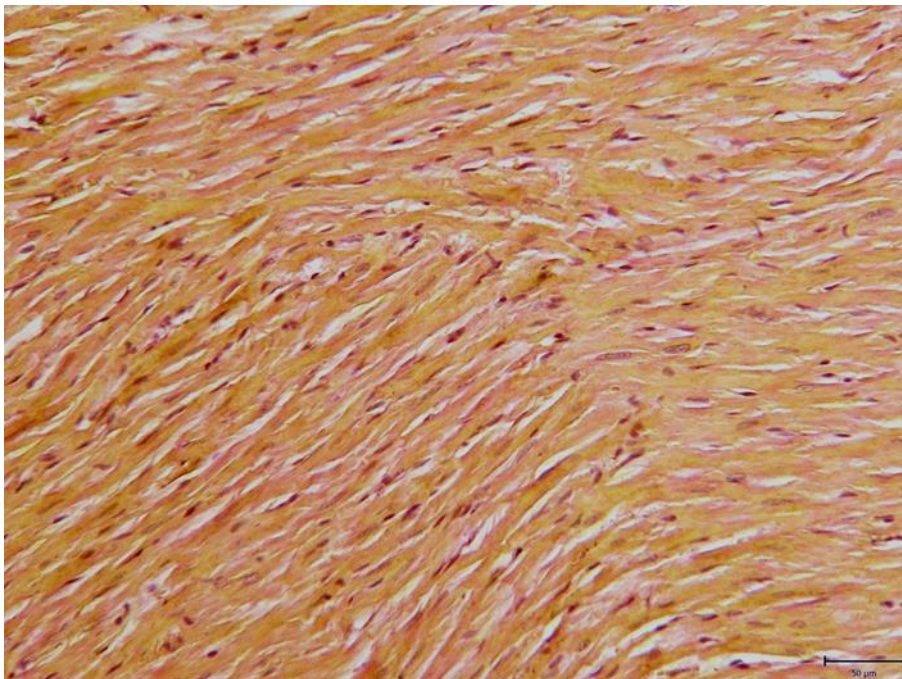


Fig. 2. Fragment of the rat myocardium of the control group. A small amount of evenly distributed connective tissue in the myocardium. Coloring by Van Gizon X200.

In the animals of the experimental group throughout the experiment, the manifestations of the general toxic effect of the drug were not observed: motor activity was preserved, there were no changes in behavioral characteristics, body weight did not change. The dynamics of tissue and cellular changes in the myocardium with the introduction of bleomycin was evaluated by light microscopy.

As a result of the experimental work it was found that after the first administration of the drug in experimental animals on the 5th day the heart weight was $1.07 \text{ g} \pm 0.23 \text{ g}$ macroscopic changes in the examination of the material were not detected. At microscopic research of fabrics of heart changes of separate cardiomyocytes (CMC) in the form of contractural degeneration with segmental and / or partial-lateral lysis were observed. Fragmentation of chromatin with its peripheral location was detected in some CMC nuclei - chromatin margination, which indicates apoptosis [9]. Destruction of nexuses of excessively shortened CMC is noted.

Contractural changes are mostly found in the areas of branching (physiological disorientation), in some subendocardially located CMC necrotization without decay is observed. Fibrin overlays were determined on the endocardium. Secondary, hypoxic lesions of the CMC were manifested by subepicardial leukocyte infiltrate, in some drugs there was a subepicardial infarction.

Excessively reduced cardiomyocytes in the subepicardial layer predominated in the area of microcirculation disorders. From the vessels of the heart there are also changes: the veins were very dilated, stagnant full-blooded (sludge); postcapillary venules had swelling of the endothelium in some areas and destruction of the walls - in others, there is separation of fibrin in them, there - foci of microlysis, the marginal state of lymphocytes (chemotaxis to lesions).

Damage to the right heart was manifested in the form of endocardial damage with subsequent development of necrosis and fibrosis. After the second administration, contractile degeneration of cardiomyocytes and marginal lysis of individual cardiomyocytes, damage to the microcirculatory tract and all vessels of the heart with increasing necrosis of cardiomyocytes both due to ischemia and due to apoptosis. All this indicates both direct (system of caval veins, right heart) and indirect (large circle of blood circulation) toxic effects of the drug.

On day 5 after a single injection of bleomycin, the heart weight of rats was $1.07 \pm 0.23 \text{ g}$, i.e. they did not differ from control values ($p > 0.05$). Macroscopic changes on examination

of the heart were not detected. At microscopic research of fabrics of heart changes of separate CMC in the form of contractural degeneration with segmental and partial-lateral lysis were observed. In some nuclei fragmentation of chromatin with peripheral location was noted - margination of chromatin indicates apoptosis, destruction of nexuses of the shortened CMC.

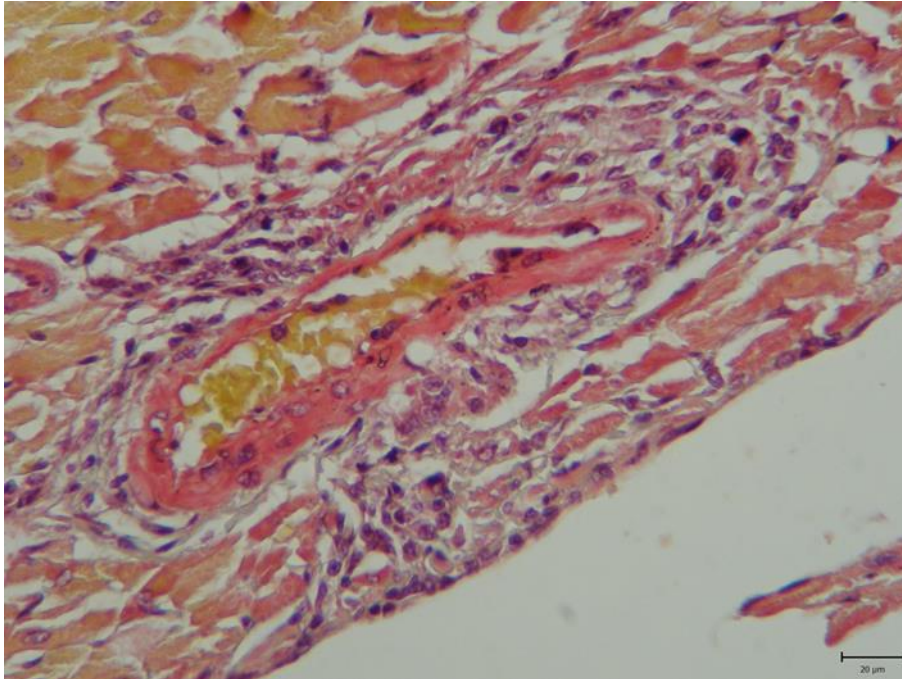


Fig. 3. Interventricular septum from the right ventricle. An artery with swelling of its walls within 2/3 of the perimeter. Microthrombi. Massive leukocyte infiltrate spreads to the endocardium Hematoxylin-eosin staining, X200

Contractural changes were more pronounced in the areas of branching (physiological disorientation) of muscle fibers. In some subendocardially located CMC necrotization without disintegration is observed (fig. 4). On the surface of the endocardium in some places was the imposition of fibrin. Secondary hypoxic lesions of the CMC were manifested by single small subepicardial foci of leukocyte infiltration, in some drugs was determined by small focal subepicardial infarction.

The presence of microcirculatory disorders is confirmed by the phenomena of stasis, the formation of sludges, the phenomena of erythrocyte lysis in the postcapillary channel with the marginal state of leukocytes. Often in subendocardial sites microhematomas were determined (fig. 5).

Subsequently, microscopic examination of heart tissue showed changes in individual cardiomyocytes (CMC) in the form of contractile degeneration with segmental and / or partial-lateral lysis (Fig. 5).

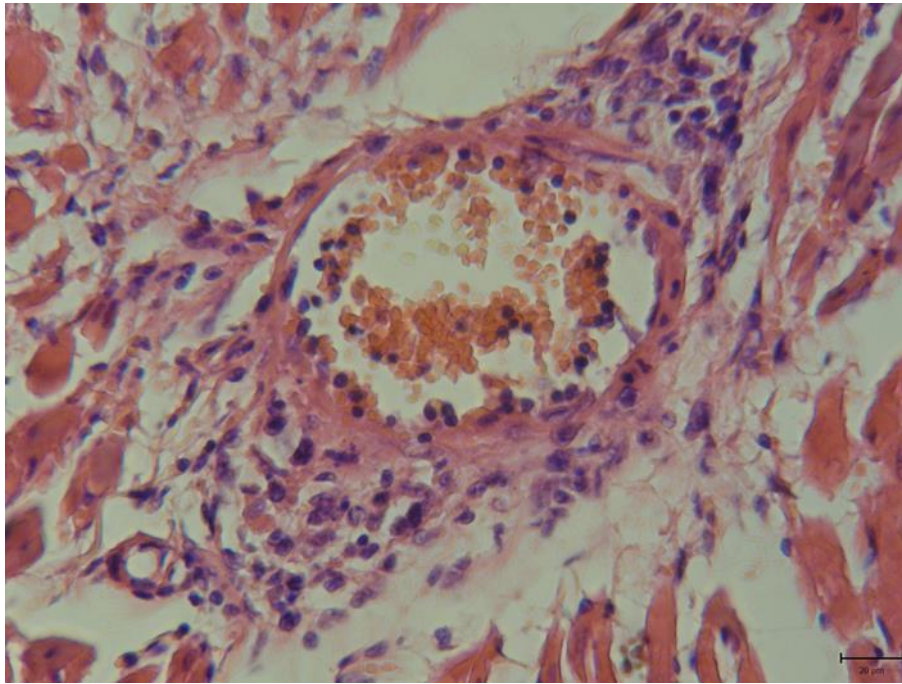


Fig. 4. Pronounced perivascular infiltration with destruction of the vessel wall and CMC (in the infiltrate mainly elements of monocytic and lymphoid series) Hematoxylin-eosin staining, X200

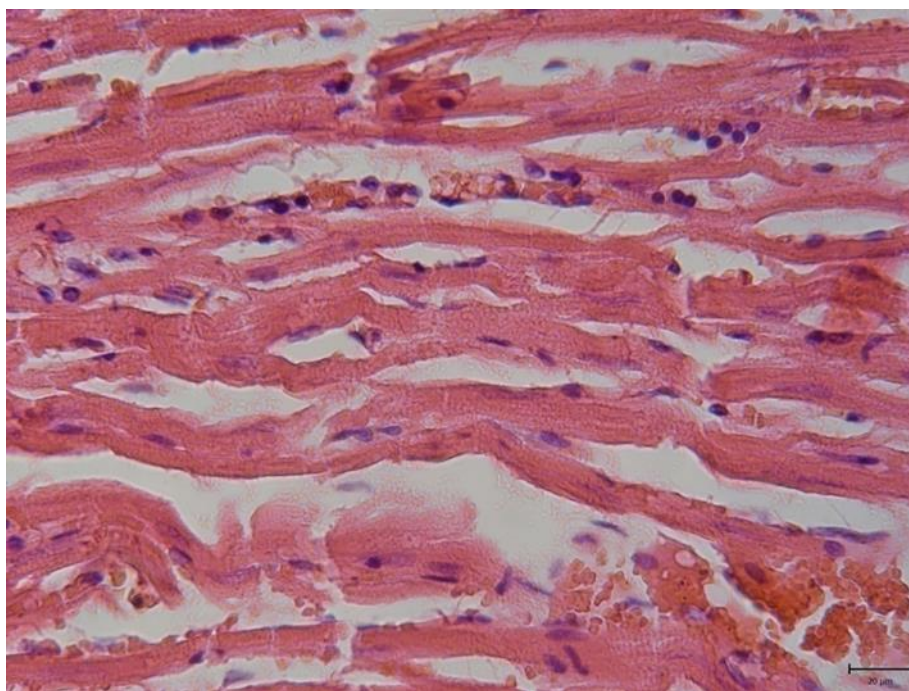


Fig. 5. Disorders of blood microcirculation: stasis, sludge (coin columns), erythrolysis in postcapillaries with marginal leukocytes; microhematoma. Destruction of some CMC nexuses, lysis of some of them. Hematoxylin-eosin staining, X200

Fragmentation of chromatin with its peripheral location - chromatin margination - was detected in some CMC nuclei. These changes are regarded as a manifestation of apoptosis. Destruction of nexuses of excessively shortened CMC is noted. Contractural changes are more pronounced in the areas of branching (physiological disorientation), in some subendocardially located CMC necrotization without decay is observed. Moderate fibrin overlays were determined on the endocardium (Fig. 6).

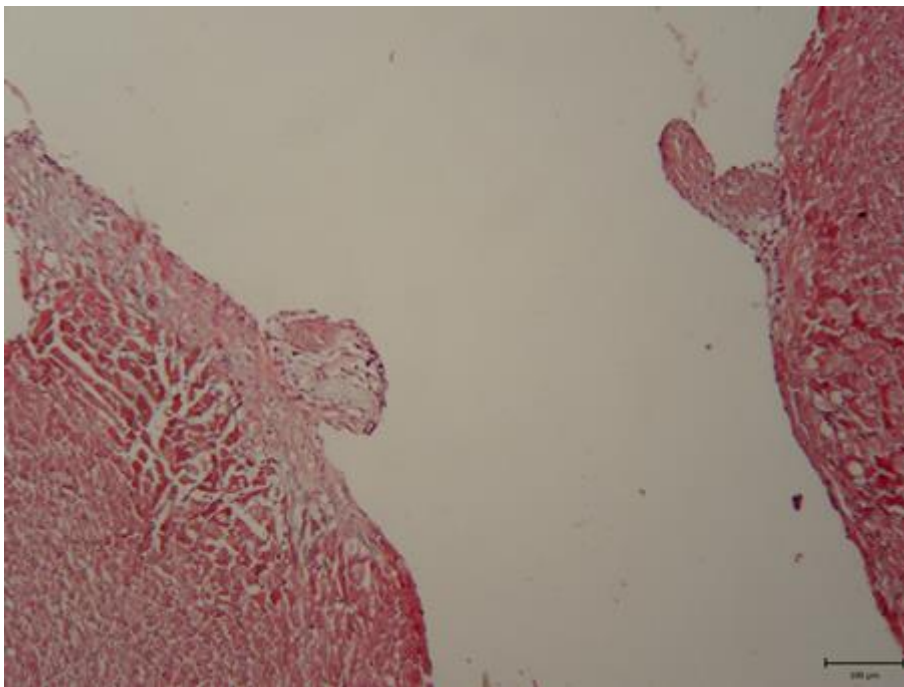


Fig. 6. Fibrosing subendocardial layer of necrotized myocardium. On the surface of the bases of damaged trabeculae - proliferation of mesenchymal tissue. In the lower left corner - the focus of CMC necrosis Hematoxylin-eosin staining, X200

Secondary lesions of CMC of hypoxic nature were manifested by subepicardial leukocyte infiltrates, and in some cases in the form of foci of subepicardial infarction.

Excessive contraction of cardiomyocytes in the subepicardial layer was a common phenomenon, most pronounced in areas of microcirculation. Major microcirculatory changes included venous plethora, signs of stasis, and endothelial dysfunction. Changes in the postcapillary segment were a typical phenomenon: in some areas endothelial edema was observed, and in others - destruction of the walls. In these zones fibrin separation is often observed, and also the centers of microlysis, marginal standing of lymphocytes which testifies to an active chemotaxis to the centers of damage are defined.

Damage to the right heart in the form of endocardial damage with the subsequent development of necrosis and fibrosis deepens after the second injection of bleomycin. At the

same time there is a contractural degeneration of cardiomyocytes and regional lysis of separate cardiomyocytes, damage of a microcirculatory channel and all vessels of heart with increase in a necrosis of cardiomyocytes both at the expense of ischemia, and owing to development of an apoptosis. and indirect (large circle of blood circulation) toxic effects of the drug.

Contracture of the CMC of the subepicardial layer prevailed in the foci of developing microcirculation disorders (Fig. 7). So in vessels of a microcirculatory channel stasis, sludge were found. The venous part of the vascular network is stagnantly full-blooded, the veins are overstretched, lining their endothelium is swollen, somewhere exfoliated.

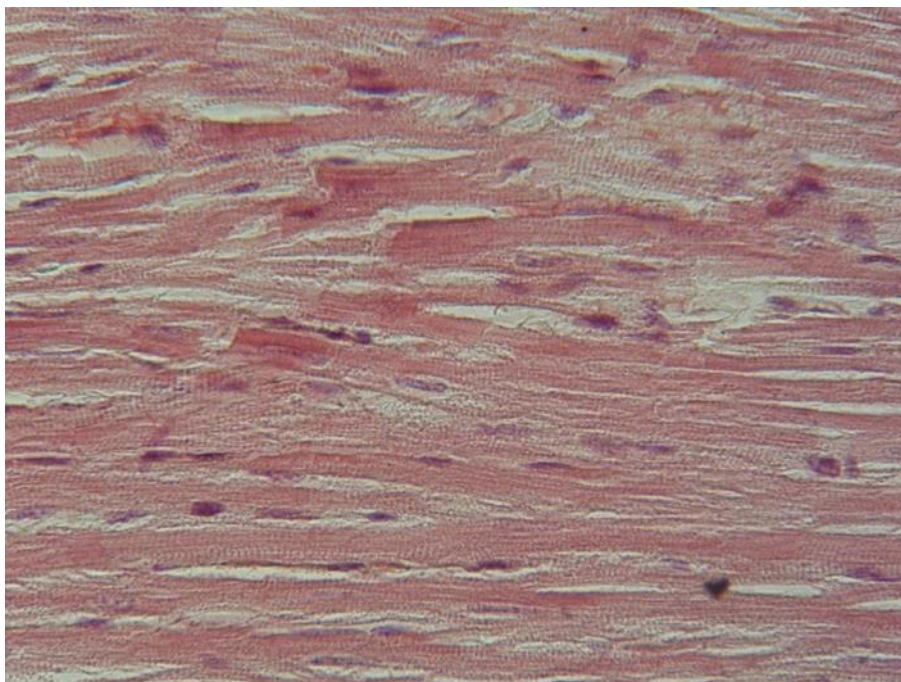


Fig. 7. The middle circular layer of the left ventricular myocardium is the least changed, but there is a tendency to contractural degeneration of the CMC and dissociation of myofibrils Hematoxylin-eosin staining, X200

In the lumen of the vessels there was separation of fibrin, marginal standing of lymphocytes (chemotaxis to the lesion); in capillaries in some places at the place of destruction of walls of capillaries free erythrocytes. In the arteries there was swelling of all components of the walls and perivascular space, developed focal leukocyte infiltration, in some areas accompanied by necrobiosis and necrosis of the elements of the artery wall. The nuclei of smooth muscles cells consist of deep chromatin; there is swelling of the epithelium with focal desquamation and the formation of parietal thrombi

Conclusion. Thus, even with a single injection of bleomycin, inflammatory-dystrophic changes of the myocardium are observed.

References:

1. Cabrera S, Maciel M, Hernández-Barrientos D, Calyeca J, Gaxiola M, Selman M, Pardo A. Delayed resolution of bleomycin-induced pulmonary fibrosis in absence of MMP13 (collagenase 3). *Am J Physiol Lung Cell Mol Physiol*. 2019 May 1;316(5):L961-L976. doi: 10.1152/ajplung.00455.2017. Epub 2019 Feb 20. PMID: 30785343.
2. Barkat MT, Abdel-Aziz RTA, Mohamed MS. Evaluation of intralesional injection of bleomycin in the treatment of plantar warts: clinical and dermoscopic evaluation. *Int J Dermatol*. 2018 Dec;57(12):1533-1537. doi: 10.1111/ijd.14092. Epub 2018 Jun 15. PMID: 29907964.
3. Yu Z, Yan B, Gao L, Dong C, Zhong J, D Ortenzio M, Nguyen B, Seong Lee S, Hu X, Liang F. Targeted Delivery of Bleomycin: A Comprehensive Anticancer Review. *Curr Cancer Drug Targets*. 2016;16(6):509-21. doi: 10.2174/1568009616666151130213910. PMID: 26632436.
4. Bleomycine. Rx. Retrieved from: <https://reference.medscape.com/drug/bleomycin-342113>
5. Didagelos M, Boutis A, Diamantopoulos N, Sotiriadou M, Fotiou C. Bleomycin cardiotoxicity during chemotherapy for an ovarian germ cell tumor. *Hippokratia*. 2013 Apr;17(2):187-8. PMID: 24376332; PMCID: PMC3743631.
6. Henry's Clinical Diagnosis and Management by Laboratory Methods by Richard A. McPherson, Matthew R. Pincus NY., Elsevier; 24th edition 2021 1618 p.
7. Zaporozhyan VM, Aryaev ML Bioethics and biosafety. K.: Zdorov'ya, 2013. - 456 p.
8. Khalafyan AA Statistica 6. Mathematical statistics with elements of the theory of probability. / A. A. Khalafyan M., Binom, - 2011 – 326 p.
9. Yang X, Li G, Yang T, Guan M, An N, Yang F, Dai Q, Zhong C, Luo C, Gao Y, Das S, Xing Y, Shang H. Possible Susceptibility Genes for Intervention against Chemotherapy-Induced Cardiotoxicity. *Oxid Med Cell Longev*. 2020 Oct 13;2020:4894625. doi: 10.1155/2020/4894625. PMID: 33110473; PMCID: PMC7578723.