

MULTIPLE INTERVAL DEBULKING SURGERY IN RECURRENT UTERINE SARCOMA (CASE REPORT)

Chetverikov S., Maksymovskiy V., Atanasov D., Chetverikov M., Chetverikova-Ovchynnyk V.

*Center of Reconstructive and Renovative Medicine (University Clinic)
of Odesa National Medical University, Surgery Department №3, Ukraine*

For some primary localizations of abdominal tumors (for example, ovarian cancer, colorectal cancer), the effectiveness of cytoreductive surgery has been proven, which creates a favorable basis for further anti-tumor drug or radiation therapy. But often there is a question of feasibility and possibility of cytoreductive surgery, especially in somatically severe condition patients and patients with tumor-related complications. Another group of patients in whom cytoreductive surgery is debatable are patients with radio- and chemoresistant tumors of the abdominal cavity, radical removal of which is not possible, and there is no alternative therapy. Uterine leiomyosarcoma is a rare gynecologic malignancy associated with a high recurrence rate and a poor prognosis. The role of cytoreductive surgery at first recurrence has rarely been studied before and has been proven in many studies [1-6] and there were reported a significant overall survival (OS) decrease after second relapse. There is no information in the literature about OS after third and more relapses. Currently, there is no single view on the systemic treatment of recurrent uterine sarcomas. The use of various chemotherapeutic treatment regimens did not allow to achieve good oncological results in the treatment of these patients according to the literature [7-10]. The use HIPEC in recurrent uterine sarcomas is also still controversial, single literature data [11-13] do not allow to include it to the treatment guidelines.

Case Report/Case Presentation. We report a case of a 61-year-old woman, who had been suffering from multiple relapses of uterine sarcoma treated by multiple cytoreduction operations.

1992-01-01 - According to the data of pelvic ultrasound there were signs of subserosal myoma up to 13 mm in diameter.

1998-07-12 - Another pelvic ultrasound was without any dynamics.

2011-05-04 - As stated in the pelvic ultrasound: *"Intramural node measuring 92x85x79 mm in the anterior wall of the uterus, the presence of free fluid up to 50 ml in the Douglas space."* The patient was offered surgery at another medical center.

2015-05-11 - Went to the doctor with complaints of acute pain in the hypogastric region, fever up to 38°C.

2015-05-11 - The ultrasound revealed: *"The myometrium is inhomogeneous with an echopositive formation on the anterior wall measuring 92x89 mm and another in the area of the uterine fundus measuring 116x94 mm. The echostructure of the nodes is heterogeneous."*

2015-05-12 - She was hospitalized for urgent surgical treatment. The operation volume was: *"Laparotomy. Uterine tumor biopsy with urgent intraoperative histological examination. (Study result: leiomyosarcoma of the uterus). Hysterectomy with ovaries. Omentectomy"*.

2015-05-22 - According to postoperative histological examination: *"20x12x10 mm G-2 uterine leiomyosarcoma with necrosis and hemorrhage, metastatic leiomyosarcoma in the right ovary"*.

2015-05-29 - As stated in tumor immunohistochemistry: *"Ki67 = 20%, Smooth Muscle Actine (1A4) - Actine positive reaction"*.

2015-10-03 - The ultrasound revealed: *"On the right side of the abdominal cavity at the level of the upper anterior iliac bone under the aponeurosis there is hypoechogenic ovoid formation with distinct borders and homogeneous structure."*

2015-12-03 - Went to the doctor with complaints of abdominal pain, bloating, delayed stool, episodes of dizziness, difficulty breathing and palpitations after lying down. Went to the computed tomography (CT), Fig. 1.

2015-12-05 - At the Ukrainian National Cancer Institute, she underwent the first cytoreductive operation: *"Removal of a tumor of the retroperitoneal space, retroperitoneal tissue. Resection of the loop of the small intestine. Appendectomy. Cystectomy of liver cyst."*

2016-04-06 - The patient was admitted to the surgical department of the Center of Reconstructive and Renovative Medicine (University Clinic) of Odesa National Medical University (UC ONMedU) with a similar clinical picture. The CT was performed (Fig.2).

2016-04-07 - The operation was performed: *"Removal of a giant tumor of the pelvis, abdominal cavity and retroperitoneal space. Right hemicolectomy. Removal of tumor metastasis in the postoperative scar along with the skin, parietal peritoneum and paravesical tissue."*

2016-06-08 - 2 courses of polychemotherapy according to the CYVADIC scheme were conducted (cyclophosphamide, vincristine, doxorubicin and dacarbazine).

2016-06-25 - She was hospitalized to the UC ONMedU, according to ultrasound of the pelvis: *"Multiple formations up to 15 mm in diameter."* The operation was performed: *"Laparoscopy. Hyperthermic intraperitoneal chemotherapy (HIPEC) - (doxorubicin 20 mg, cisplatin 80 mg)."*

2016-12-02 - The patient was admitted to the UC ONMedU with the complaints of pain in the hypogastrium. CT: *"Tumor of the right iliac region up to 70mm."* The operation was performed: *"Laparotomy. Removal of the tumor of the right iliac region. Ventral hernia repair."*

2017-07-06 - As stated in CT: *"Carcinomatosis of the peritoneum, ascites. Cyst of the right lobe of the liver. Cholecystolithiasis."*

2017-07-08 - She was hospitalized to the UC ONMedU with the complaints of pain in the hypogastric and mesogastric regions, weight loss, weakness. The operation was performed: *"Removal of recurrent tumors of the abdominal cavity. Resection of the small intestine."*

2017-10-26 - The patient was admitted to the UC ONMedU due to pain in the left iliac region, constipation. CT: *"Two hypervascular formations 29x25x20mm on the parietal peritoneum and 24x7x4mm in the mesentery of the sigmoid colon."*

2017-10-27 - The operation was performed: *"Removal of tumor nodes of the abdominal cavity."*

2018-04-24 - She was hospitalized in UC ONMedU with symptoms of chronic small bowel obstruction, acute occlusive thrombosis of the pelvic and femoral veins. The CT was performed (Fig. 3).

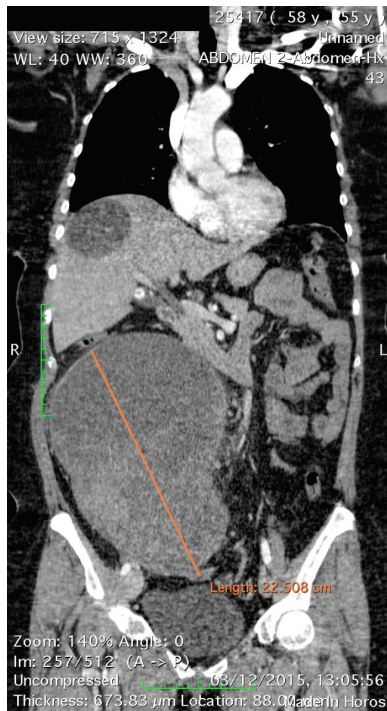


Fig. 1. CT 12/03/2015 - "Below the distal edge of the liver, the formation of an inhomogeneous structure measuring 187x225x145 mm. Two nodes in the lower sections measuring 50x41 mm and 54x35 mm. Cystoma of the VIII segment of the liver measuring 65x49x63mm. Gallbladder with multiple stones up to 16x10 mm»

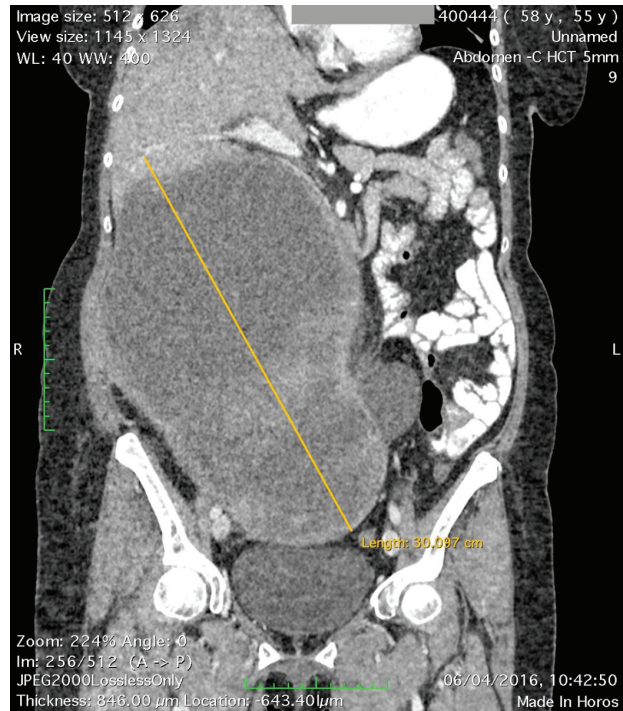


Fig. 2. CT 04/06/2016 - "Below the distal edge of the liver there is a tumor measuring 300x232x193mm inhomogeneous structure, adjacent to the vascular bundle, narrowing the lumen of the inferior vena cava, shifts the loops of the intestine laterally to the left. Right ureterohydronephrosis. Gallbladder with stones up to 18x12 mm. Ovoid shaped neoplasms in the area of the postoperative scar of the anterior abdominal wall, homogeneous structure, size 42x34x30mm"

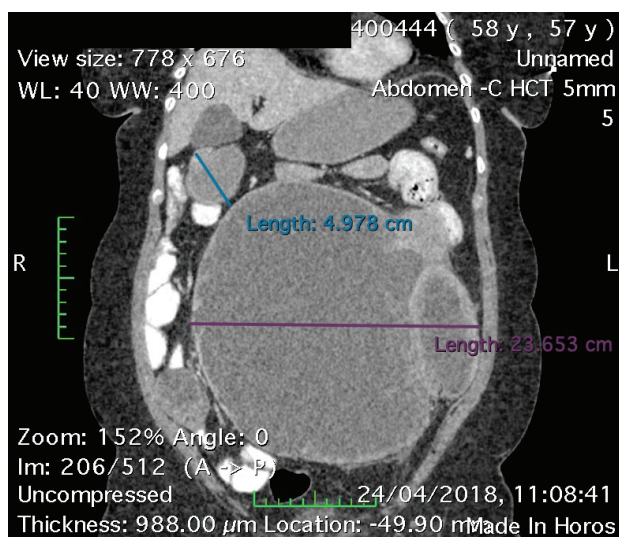


Fig. 3. CT 04/24/2018 - "A giant tumors of the abdominal cavity measuring 236x223x180mm and 50x49x20mm with a heterogeneous structure and clear borders"

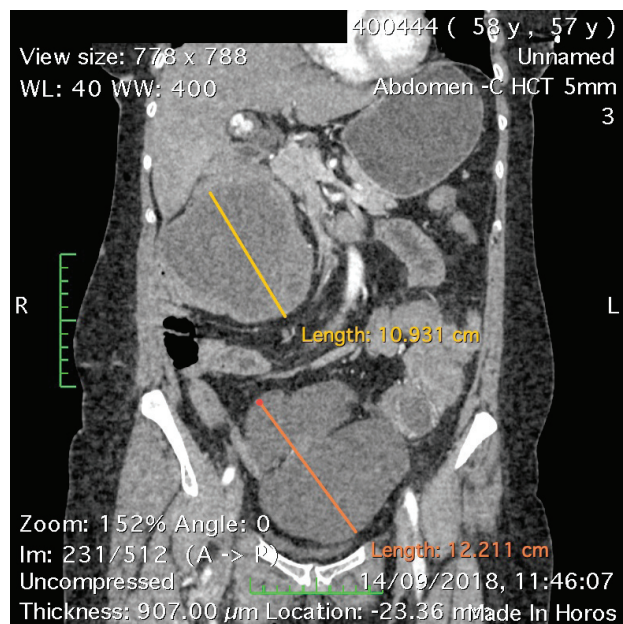


Fig. 4. CT 09/14/2018 - "Tumor nodes 129x122 mm in the pelvic cavity and 109x100 mm in the right hypochondrium of inhomogeneous consistency, irregular shape, without clear contours"

2018-04-25 - The operation was performed: "Removal of recurrent tumors of the abdominal cavity measuring 300x300x250 mm with resection of the small intestine and the formation of jejunum-jejunum and ileo-transversoanastomosis."

2018-09-14 - The patient was admitted to UC ONMedU with signs of acute calculous cholecystitis, chronic duodenal ulcer with penetration into the gallbladder, recurrent tumors of the abdominal cavity. The CT was performed (Fig. 4).

2018-09-15 - The operation was performed: "Removal of abdominal tumors. Cholecystectomy. Removal of duodenal ulcer with invasion to the gallbladder with the Judd's pyloroduodenoplasty".

2018-09-17 - The postoperative period was complicated by the leakage of the sigmoid colon sutures. It was treated conservatively due to adequate intraoperative drainage of the abdominal cavity. There were no signs of peritonitis during the observation period.

2019-03-27 - She was hospitalized to UC ONMedU with the symptoms of partial bowel obstruction. The CT was performed (Fig. 5). The operation was performed: "Laparotomy. Removal of the recurrent tumors. Resection of the jejunum."

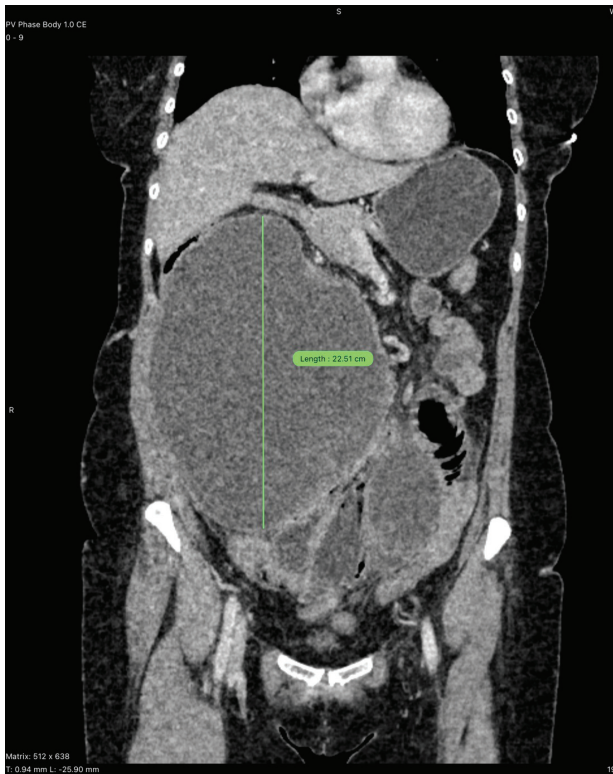


Fig. 5. CT 03/19/2019 - "Recurrent tumors of the abdominal cavity diameter 225 mm and 95 mm with a heterogeneous structure with the invasion of the jejunum"

2019-06-11 - The patient was admitted to UC ONMedU with the CT data of the tumor recurrence invaded sigmoid colon. The operation was performed: "Laparotomy. Partial parietal peritonectomy. Removal of the tumor, resection of the sigmoid colon."

2019-07-22 - She was hospitalized to UC ONMedU with the complaints of nausea, repeated vomiting, tremor of the upper limbs, shortness of breath. According to the signs of electrolyte disorders, conservative treatment with positive clinical dynamics was performed.

2019-10-03 - The patient was admitted to UC ONMedU with the CT data of two tumors of abdominal cavity up to 130 mm each. The operation was performed: "Laparotomy. Suboptimal peritonectomy. Removal of the two tumors from the right iliac and left mesogastric regions."

2020-01-30 - She was hospitalized to UC ONMedU with the CT data of the two tumors up to 12 cm of the abdominal cavity, sarcomatosis. The operation was performed: "Laparotomy. Suboptimal peritonectomy. Removal of the tumors with the resection of ileum."

During the observation period there were performed 13 surgical interventions. As a result of operations, together with the removal of more than 60 liters of tumor volume, the following were performed: extirpation of the uterus with ovaries, right colectomy, resection of the small intestine four times, resection of the sigmoid colon, resection of the duodenum, peritonectomy, cholecystectomy, appendectomy, 2 cycles of adjuvant chemotherapy and HIPEC procedure. During this entire period, with interruptions for hospital treatment, the patient works as a teacher, quality of life remains satisfactory. Patient observation continues, according to the CT-control (last time 02/12/2021) there are no signs of tumor relapse. 64 months have passed since the first clinical relapse. The overall survival rate is 69 months.

Conclusion. Cytoreductive surgery in patients with chemo- and radioresistant tumors of the abdominal cavity is the only effective method of treatment of this group of patients in addition to symptomatic therapy. Repeated early optimal cytoreduction with the maximum possible removal of all detected tumor mass and restoration of anatomical or functional integrity of the affected organs can reduce the likelihood of tumor cachexia, intoxication, anemia, thrombosis and hemorrhage, edema and dysfunction of the digestive and urinary systems. This prolongs life expectancy and increases its quality in patients with second and more uterine sarcoma relapse.

Acknowledgement. All authors approved the final manuscript as submitted and agree to be accountable for all aspects of the work.

Statement of Ethics. The research was conducted ethically in accordance with the World Medical Association Declaration of Helsinki. Written informed consent was obtained from the patient for publication of this case report and any accompanying images. The study protocol was approved by the committee on human research of Odesa National Medical University. Information revealing the subject's identity is avoided.

REFERENCES

1. Bizzarri N, Ghirardi V, Di Fiore GLM, et al. Secondary cytoreductive surgery in recurrent uterine leiomyosarcoma: a multi-institutional study. // International Journal of Gynecologic Cancer 2019;29:1134-1140.
2. Leitaio MM, Brennan MF, Hensley M, et al. Surgical resection of pulmonary and extrapulmonary recurrences of uterine leiomyosarcoma. // Gynecol Oncol 2002;87:287-94.
3. Giuntoli RL, Garrett-Mayer E, Bristow RE, et al. Secondary cytoreduction in the management of recurrent uterine leiomyosarcoma. // Gynecol Oncol 2007;106:82-8.
4. Bacalbasa N, Balescu I, Dima S, et al. Prognostic factors and survival in patients treated surgically for primary and recurrent uterine leiomyosarcoma: a single center experience. // Anticancer Res 2015;35:2229-34.
5. Hoang HLT, Ensor K, Rosen G, et al. Prognostic factors and survival in patients treated surgically for recurrent metastatic uterine leiomyosarcoma. // Int J Surg Oncol 2014;9:19323.

6. Nakamura K, Kajiyama H, Utsumi F, et al. Secondary cytoreductive surgery potentially improves the oncological outcomes of patients with recurrent uterine sarcomas. // *Mol Clin Oncol* 2018;8:499–503.
7. Ricci S, Giuntoli RL, Eisenhauer E, et al. Does adjuvant chemotherapy improve survival for women with early-stage uterine leiomyosarcoma? *Gynecol Oncol* 2013;131:629–33.
8. Giuntoli RL, Metzinger DS, DiMarco CS, et al. Retrospective review of 208 patients with leiomyosarcoma of the uterus: prognostic indicators, surgical management, and adjuvant therapy. // *Gynecol Oncol* 2003;89:460–9.
9. Arend RC, Toboni MD, Montgomery AM, et al. Systemic treatment of metastatic/recurrent uterine leiomyosarcoma: a changing paradigm. // *Oncologist* 2018;23:1533–45.
10. Gupta AA, Yao X, et al, Sarcoma Disease Site Group and the Gynecology Cancer Disease Site Group. Systematic chemotherapy for inoperable, locally advanced, recurrent, or metastatic uterine leiomyosarcoma: a systematic review. // *Clin Oncol* 2013;25:346–55.
11. Jimenez WA, Sardi A, Nieroda C, et al. Cytoreductive surgery and hyperthermic intraperitoneal chemotherapy in the management of recurrent high-grade uterine sarcoma with peritoneal dissemination. // *Am J Obstet Gynecol* 2014;210:259.e1–259.e8.
12. Díaz-Montes TP, El-Sharkawy F, Lynam S, et al. Efficacy of hyperthermic intraperitoneal chemotherapy and cytoreductive surgery in the treatment of recurrent uterine sarcoma. // *Int J Gynecol Cancer* 2018;28:1130–7.
13. Sardi A, Sipok A, Baratti D, et al. Multi-institutional study of peritoneal sarcomatosis from uterine sarcoma treated with cytoreductive surgery and hyperthermic intraperitoneal chemotherapy. // *Eur J Surg Oncol* 2017;43:2170–7.

SUMMARY

MULTIPLE INTERVAL DEBULKING SURGERY IN RECURRENT UTERINE SARCOMA (CASE REPORT)

Chetverikov S., Maksymovskiy V., Atanasov D., Chetverikov M., Chetverikova-Ovchynnyk V.

Center of Reconstructive and Renovative Medicine (University Clinic) of Odesa National Medical University, Surgery Department №3, Ukraine

We report a case of a 61-year-old woman, who had been suffering from multiple relapses of uterine sarcoma treated by multiple cytoreduction operations.

During the observation period there were performed 13 surgical interventions. As a result of operations, together with the removal of more than 60 liters of tumor volume, the following were performed: extirpation of the uterus with ovaries, right colectomy, resection of the small intestine four times, resection of the sigmoid colon, resection of the duodenum, peritonectomy, cholecystectomy, appendectomy, 2 cycles of adjuvant chemotherapy and Hyperthermic intraperitoneal chemotherapy procedure. During this entire period, with interruptions for hospital treatment, the patient works as a teacher, quality of life remains satisfactory. Patient observation continues, according to the computed tomography control (last time 02.12.2021) there are no signs of tumor relapse. 64 months have passed since the first clinical relapse. The overall survival rate is 69 months and it has already exceeded the theoretically unattainable 5 years from the onset of the disease.

Cytoreductive surgery in patients with chemo- and radioresistant tumors of the abdominal cavity is the only effective method of treatment of this group of patients in addition to symptomatic therapy. Repeated early optimal cytoreduction with the maximum possible removal of all detected tumor mass and restoration of anatomical or functional integrity of the affected organs can reduce the likelihood of tumor cachexia, intoxication, anemia, thrombosis and hemorrhage, edema and dysfunction of the digestive and urinary systems. This prolongs life expectancy and increases its quality in patients with second and more uterine sarcoma relapse.

Keywords: debulking surgery, cytoreductive surgery, uterine sarcoma, chemotherapy, HIPEC.

РЕЗЮМЕ

МНОЖЕСТВЕННЫЕ ЭТАПНЫЕ ЦИТОРЕДУКТИВНЫЕ ОПЕРАЦИИ ПРИ РЕЦИДИВНОЙ САРКОМЕ МАТКИ (СЛУЧАЙ ИЗ ПРАКТИКИ)

Четвериков С.Г., Максимовский В.Е., Атанасов Д.В., Четвериков М.С., Четверикова-Овчинник В.В.

Одесский национальный медицинский университет, хирургическое отделение №3, Центр реконструктивной и восстановительной медицины (университетская клиника), Украина

Представлен клинический случай 61-летней женщины с многократно рецидивирующей саркомой матки, пролеченной множественными циторедуктивными операциями.

За период наблюдения выполнено 13 хирургических вмешательств. В результате операций вместе с удалением более 60 литров объема опухолевой массы выполнены: экстирпация матки с придатками, правосторонняя гемиколэктомия, четыре раза резекции тонкой кишки, резекция сигмовидной кишки, резекция двенадцатиперстной кишки, перитонэктомия, холецистэктомия, аппендэктомия, 2 цикла адьювантной химиотерапии и процедура гипертермической внутрибрюшинной химиотерапии. В течение всего этого периода, с перерывами на стационарное лечение, пациентка работала преподавателем, качество жизни остается удовлетворительным. Наблюдение за пациенткой продолжается, по данным контроля компьютерной томографии (последний раз 12.02.2021) признаков рецидива опухоли не выявлено. С момента первого клинического рецидива прошло 64 месяца. Общая выживаемость составила 69 месяцев, что уже превышает теоретически недостижимые 5 лет с момента начала заболевания.

Циторедуктивная хирургия у пациентов с химио- и радиорезистентными опухолями брюшной полости является единственным эффективным методом лечения этой группы пациентов в дополнение к симптоматической терапии. Повторная ранняя оптимальная циторедукция с максимально возможным удалением всей обнаруженной опухолевой массы и восстановлением анатомической или функциональной целостности пораженных органов понижает вероятность опухолевой кахексии, интоксикации, анемии, тромбозов, кровоизлияний, отеков, дисфункции пищеварительной и мочевыводящей систем, что увеличивает продолжительность жизни и повышает ее качество у пациентов со вторым и более двух рецидивами саркомы матки.

რეზიუმე

მრავლობითი საეტაპო ციტორედუქციული ოპერაციები საშვილოსნოს მიომის რეციდივის დროს (შემთხვევა პრაქტიკიდან)

სხეტვერიკოვი, ვმაქსიმოვსკი, დატანასოვი, მხეტვერიკოვი, ვხეტვერიკოვა-ოფინინიკი

ოღვის ეროვნული სამედიცინო უნივერსიტეტი, №3 ქირურგიული განყოფილება, რეკონსტრუქციული და აღდგენითი მედიცინის ცენტრი (საუნივერსიტეტო კლინიკა), უკრაინა

საშვილოსნოს ლეიომიოსარკომა იშვიათი ავთვისებიანი ვინეკოლოგიური ახალწარმონაქმნია, რეციდივების მაღალი სისშირით და ცუდი პროგნოზით.

სტატიაში წარმოდგენილია საშვილოსნოს მრავალჯერადად მორეციდივე სარკომის მქონე 61 წლის ქალის კლინიკური შემთხვევა, რომელსაც მკურნალობდნენ მრავლობითი ციტორედუქციული ოპერაციებით.

დაკვირვების პერიოდში განხორციელდა 13 ქირურგიული ჩარევა. ოპერაციების შედეგად, 60 ლიტრის მოცულობის სიმსივნური მასის მოცილებასთან ერთად, ჩატარდა: საშვილოსნოს და დანამატების ექსტირპაცია, მარჯვენამხრივი ჰემიკოლექტომია, წვრილი ნაწლავის რეზექცია ოთხჯერ, სიგმოიდური ნაწლავის რეზექცია, თორმეტგოჯა ნაწლავის რეზექცია, პერიტონექტომია,

ქოლეცისტექტომია, აპენდექტომია, ადიუვანტური ქიმიოთერაპიის ორი კურსი და მუცლის ღრუს შიდა პიპერთერმიული ქიმიოთერაპიის პროცედურა. ამ პერიოდის განმავლობაში, შესვენებებით სტაციონარული მკურნალობის დროს, პაციენტი მუშაობდა მასწავლებლად, სიცოცხლის ხარისხი დამაკმაყოფილებელი იყო. დაკვირვება პაციენტზე გაგრძელდა; კომპიუტერული ტომოგრაფიის საკონტროლო მონაცემების მიხედვით (ბოლოს – 12.02.2021) სიმსივნის რეციდივის ნიშნები არ გამოვლინდა. პირველი კლინიკური რეციდივის მომენტიდან გასულია 64 თვე. საერთო გადარჩენადობამ შეადგინა 69 თვე, რაც უკვე აღემატება თეორიულად მიუღწევებელ 5 წელს დაავადების დაწყების მომენტიდან.

ციტორედუქციული ქირურგია პაციენტებში მუცლის ღრუს ქიმიო- და რადიორეზისტენტული სიმსივნეებით წარმოადგენს ამ ჯგუფის პაციენტების მკურნალობის ერთადერთ ეფექტურ მეთოდს, სიმპტომურ თერაპიასთან ერთად. განმეორებითა აღრეულმა ოპტიმალურმა ციტორედუქციამ აღმოჩენილი სიმსივნური მასის მაქსიმალურად შესაძლო ამოკვეთით და დაზიანებული ორგანოების ანატომიური და ფუნქციური მთლიანობის აღდგენით შესაძლოა შეამციროს სიმსივნური კახეკსიის, ინტოქსიკაციის, ანემიის, თრომბოზების, სისხლჩაქცევების, შეშუპების, საჭმლის მომხელებელი და საშარდე სისტემების დისფუნქციის ალბათობა, რაც ზრდის სიცოცხლის ხანგრძლივობას და აუმჯობესებს მის ხარისხს პაციენტებში საშვილოსნოს სარკომის მეორე და მეტი რეციდივით.

COMPARATIVE ANALYSIS OF NEUROSURGICAL ASPECTS OF NEONATAL INTRAVENTRICULAR HEMORRHAGE TREATMENT

^{1,2}Dvalishvili A., ³Khinikadze M., ²Gegia G., ⁴Orlov M.

¹New Vision University; ²O. Gudushauri National Medical Centre, Department of Neurosurgery;

³New Vision University Hospital, Tbilisi Georgia; ⁴The State Institution Romodanov Neurosurgery Institute National Academy of Medical Sciences of Ukraine, Head of Neurosurgery Vascular Department, Kiev Ukraine

Damage of the central nervous system is one of the leading causes of early illness, disability and death in newborns. In preterm infants, intraventricular hemorrhage is one of the most difficult and common forms of brain damage. Intraventricular hemorrhage frequently causes severe neurological damage and fatality in children. Among the neonates with gestational age of less than 29 weeks, intraventricular hemorrhage rate ranges from 20% to 30% [5]. For the neonates weighing less than 1500 grams, the probability of developing the intraventricular hemorrhage ranges between 15% -20%, [9]. The lower the gestational age and body mass is, the more common the severe intraventricular hemorrhages are. Murphy et al. published the study showing that the half of newborns with intraventricular hemorrhage do not develop ventricular dilatation, the quarter develops non-progressive ventricular dilatation, and the remaining quarter de-

velops ventricular dilatation with posthemorrhagic hydrocephalus [1]. Several methods are currently available for treatment of posthemorrhagic progressive ventricular dilatation, including: 1. Serial lumbar/ventricular puncture 2. Ventriculostomy 3. Implantation of ventricular subcutaneous reservoir 4. Ventriculo-subgaleal shunting 5. Endoscopic ventricular irrigation [6].

There is a lot of discussion throughout the world literature concerning the safest and most optimal methods [6-8]. This study seeks to present the results obtained by our clinic. Three methods were used in our medical center for treatment of: 1. Serial ventricular/lumbar puncture 2. Ventriculostomy 3. Implantation of ventricular subcutaneous reservoir.

Material and methods. 39 medical cases were studied retrospectively, all the patients were treated at the Neonatology Department of Ghudushauri National Medical Center, in 2016-