

11. Van Wijk R, Van Wijk EPA, Pang J, Yang M, Yan Y, Han J. Integrating Ultra-Weak Photon Emission Analysis in Mitochondrial Research. *Front. Physiol.* 2020; 11 :717. doi: 10.3389/fphys.2020.00717
12. Yang M, Ding W, Liu Y, Fan H, Bajpai RP, Fu J, et.al. Ultra-weak photon emission in healthy subjects and patients with type 2 diabetes: evidence for a non-invasive diagnostic tool. *Photochem. Photobiol. Sci.* 2017; 16 :736–743. doi: 10.1039/c6pp00431h
13. Zapata F, Pastor-Ruiz V, Ortega-Ojeda F, Montalvo G, Ruiz-Zolle AV, García-Ruiz C. Human ultra-weak photon emission as non-invasive spectroscopic tool for diagnosis of internal states – A review. *Journal of Photochemistry and Photobiology B: Biology.* 2021; 216 :1011–1344. doi.org/10.1016/j.jphotobiol.2021.112141.
14. Zhdan VM, Holovanova IA, Khorosh MV, Tovstiak MM, Zinchuk AM. Comparative analysis of the dynamics of modified risk factors of non-communicable diseases among the population of China and Ukraine. *Wiad Lek.* 2019; 72(5 cz 2) :1108–1116. PMID: 31175754.
15. Zhunina OA, Yabbarov NG, Grechko AV, Starodubova AV, Ivanova E, Nikiforov NG, Orekhov AN The Role of Mitochondrial Dysfunction in Vascular Disease, Tumorigenesis, and Diabetes. *Front. Mol. Biosci.* 2021; 8 :671908. doi: 10.3389/fmolb.2021.671908

Стаття надійшла 30.01.2022 р.

DOI 10.26724/2079-8334-2023-1-83-143-147

UDC 618.19-006.6-06:616.428-076]-091

**R.P. Nikitenko, V.M. Kosovan, K.O. Vorotyntseva, E.A. Koichev, S.P. Degtyarenko,
O.M. Kvasha, V.K. Likhachov¹**
Odesa National Medical University, Odesa
¹Poltava State Medical University, Poltava

IMPROVEMENT OF THE ALGORITHM FOR INTRAOPERATIVE DIAGNOSTICS OF BREAST CANCER METASTASIS USING SENTINEL LYMPH NODE STAINING

e-mail: vladimir.lihachev@gmail.com

Lymphatic metastasis is one of the most important causes of local BC recurrence and an unfavourable prognosis factor. With the beginning of application in the surgical practice of staining sentinel lymph nodes using modern dyes (Patent Blue, ICG), the approach to determining the extent of surgical intervention has changed radically. Performing the staining of sentinel lymph nodes in breast tumours allows for reducing the trauma of surgical intervention as much as possible (due to the refusal of axillary lymph node dissection), as a result of which the number of postoperative complications is minimised. The purpose of the study was to improve the algorithm for intraoperative detection of sentinel lymph nodes in patients with breast cancer. Between 2016 and 2021, 200 patients with T1-T3N0M0 breast cancer were operated on at the Odesa Regional Clinical Hospital using two dyes: Patent Blue and ICG. The proposed algorithm for diagnosis and treatment of breast cancer allows most cases to abandon traumatic operations in favour of organ-preserving operations with biopsy of sentinel lymph nodes.

Key words: breast cancer, sentinel lymph nodes, intraoperative staining of lymph nodes, biopsy.

**Р.П. Нікітенко, В.М. Косован, К.О. Воротинцева, Є.А. Койчев, С.П. Дегтяренко,
О.М. Кваша, В.К. Ліхачов**

УДОСКОНАЛЕННЯ АЛГОРИТМУ ІНТРАОПЕРАЦІЙНОЇ ДІАГНОСТИКИ МЕТАСТАЗУВАННЯ РАКУ МОЛОЧНОЇ ЗАЛОЗИ ШЛЯХОМ ФАРБУВАННЯ «СТОРОЖОВИХ» ЛІМФОВУЗЛІВ

Лімфогенне метастазування є однією з найважливіших причин виникнення місцевого рецидиву раку молочної залози та несприятливим фактором прогнозу. З початком застосування в хірургічній практиці методики фарбування сторожових лімфовузлів з використанням сучасних барвників (Patent Blue, ICG), кардинально змінився підхід до визначення обсягу оперативного втручання. Виконання фарбування сторожових лімфовузлів при пухлинах молочної залози дозволяє максимально зменшити травматичність хірургічного втручання (за рахунок відмови від аксиллярної лімфодиссекції), внаслідок чого мінімізується кількість післяопераційних ускладнень. Метою даної роботи було удосконалення алгоритму інтраопераційного виявлення «сторожових» лімфовузлів у хворих на рак молочної залози. У період з 2016 по 2021 р. на базі Одеської обласної клінічної лікарні було прооперовано 200 пацієнток з раком молочної залози T1-T3N0M0, з використанням двох барвників: Patent Blue та ICG. Запропонований алгоритм діагностики та лікування раку молочної залози дозволяє в переважній більшості випадків відмовитися від травматичних операцій на користь органозберігаючих операцій з біопсією «сторожових» лімфовузлів.

Ключові слова: рак молочної залози, сторожові лімфовузли, інтраопераційне фарбування лімфовузлів, біопсія.

The study is a fragment of the research project "Development and implementation of new methods of intraoperative diagnosis of sentinel lymph nodes in patients with stomach and uterine cancer", state registration No. 0119U003578.

Breast cancer (BC) is women's most common oncological disease in various countries and ranks first among other forms of female oncology [1, 2, 14]. Despite the early diagnosis of oncological diseases, and the presence of screening programs for the detection of breast cancer, more than 20 % of patients at the time of detection of this disease already have signs of metastasis of the tumour process [2, 4].

Modern surgery's possibilities in treating breast cancer patients directly depend on the damage to the lymph nodes [1, 7, 13]. And the degree of damage to the lymph nodes directly depends on the size of the breast tumor, and as it increases, the probability of metastases in such lymph nodes increases [3, 7, 9, 10].

Lymphatic metastasis is one of the most important causes of local BC recurrence and an unfavourable prognosis factor [4, 14, 15]. According to some studies, five-year survival did not exceed 45 % in patients with breast cancer and lesions of the regional lymph nodes (LNs), while five-year survival in patients without lesions of the lymph nodes increased to 70 % [2, 6, 11].

Unfortunately, no single method still allows the detection of regional LN lesions in patients with BC [1, 2, 3, 9]. The main criterion that can indirectly evaluate the metastatic lesion of the LNs is the size of the nodes [8, 14]. At the same time, the increased size of LNs does not always indicate their involvement in the tumour process [5, 15]. On the other hand, there are reports that even with a slight increase in LNs (less than 5 mm in diameter), they were metastatic in 15 % of patients [8, 9, 12].

The main non-invasive methods of determining affected regional lymph nodes are ultrasound, CT, and MRI, which are more informative in young patients with a predominance of the epithelial component in the mammary glands [3, 10]. Finding a sentinel lymph node gives surgeons a considerable advantage in solving the issue of the volume of surgical intervention. In addition, it makes it possible to reduce the amount of axillary lymph node dissection, which, thus, significantly reduces the number of complications and improves the patient's quality of life [1, 12, 13]. However, the above studies do not have the appropriate sensitivity and specificity for the assessment of regional metastasis in general and the detection of damage to a group of lymph nodes [1, 8], which indicates the need to search for new methods for diagnosing metastasis [3, 13].

Detecting sentinel LNs is essential for diagnosing and determining the intensity of malignant growth since the further spread of most malignant neoplasms begins with metastasis to regional lymph nodes [7, 15]. In modern breast surgery, Patent Blue and fluorescent ICG (indocyanine green) dyes are used to detect such lymph nodes. They allow the most accurate sentinel lymph node detection [5, 8, 13, 14].

Mastectomy is considered a common surgical treatment method for patients with breast cancer [5, 8, 13, 14]. However, this operation is traumatic and is associated with many intraoperative and postoperative complications and a significant decrease in patients' quality of life [1-3]. But with the beginning of application in surgical practice of staining sentinel lymph nodes using modern dyes (Patent Blue, ICG), the approach to determining the extent of surgical intervention has changed radically [6, 12]. Performing the staining of sentinel lymph nodes for BC allows for reducing the trauma of surgical intervention as much as possible and significantly minimises the number of postoperative complications [4, 9, 11].

The purpose of the study was to improve the algorithm for intraoperative detection of sentinel lymph nodes in breast cancer patients by using Patent Blue and ICG dyes.

Materials and methods. Between 2016 and 2021, 200 patients with T1-T3N0M0 breast cancer were operated on at the Odesa Regional Clinical Hospital using two dyes (Patent Blue, Guerbet, Germany and fluorescent dye ICG, Aurolab, India). The patients were aged from 35 to 68 years. All 200 patients were divided into two groups. In group I (n=100), staining of lymph nodes was performed using Patent Blue dye, and in group II (n=100) – using fluorescent dye ICG.

All patients underwent a preoperative examination, which included: a blood test, biochemical blood test, coagulogram, ECG, mandatory trepan biopsy of the tumour with histological analysis and immunohistochemistry with the study of molecular biological markers (ER, clone 6F11, PR, clone16, Her-2, Ki-67), ultrasound examination of mammary glands and lymph nodes, digital mammography in two projections, computer tomography of the chest, abdominal cavity and pelvic organs with intravenous contrast. All operations were performed under endotracheal anesthesia with the patients in the supine position.

All 100 patients of the 1st group were injected subcutaneously with the Patent Blue dye along the outer edge of the areola (Fig. 1), in the amount of 2 ml of the diluted dye, to allow it to spread through the lymphatic system. The standard time interval for the appearance of a stained lymph node was 15–20 minutes (Fig. 2). Then the stained sentinel lymph nodes were removed (Fig. 3), and biopsies were sent for pathomorphological examination. Please note that Patent Blue dye does not give a bright color to the sentinel lymph node (Figs. 2, 3).

In group II, the sentinel lymph nodes were stained using the ICG fluorescent dye, which was injected subcutaneously into the shoulder on the affected side of the mammary gland in the course of lymph outflow from the arm to the mammary gland. This method of staining lymph nodes is based on the dye's luminescence effect when exposed to a specific wavelength's light [6, 11]. After administration of the ICG dye, green-stained sentinel lymph nodes (Fig. 4) were determined 15 minutes later, followed by their

biopsy. In Figure 4, we can see that with ICG dye, bright staining of the sentinel lymph node occurs (in contrast to the pale staining with Patent Blue dye).

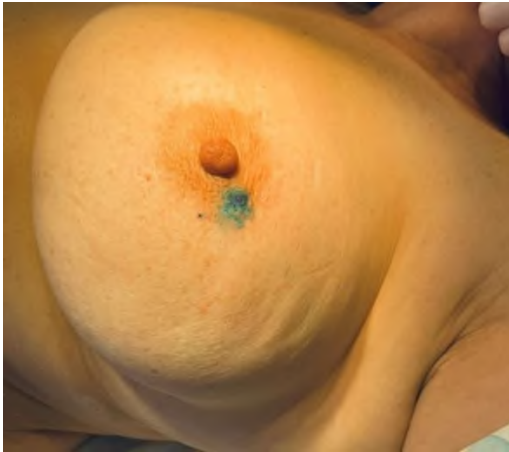

Fig. 1. Injection of Patent Blue dye subcutaneously along the outer edge of the areola.

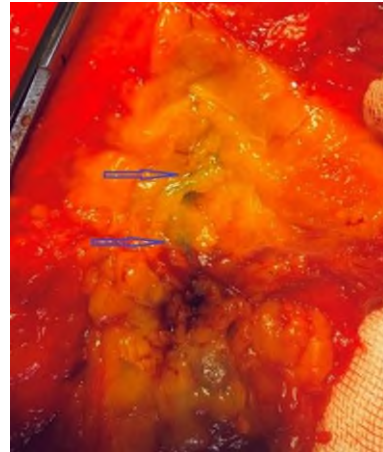

Fig. 2. Lymph nodes are stained with Patent Blue dye.

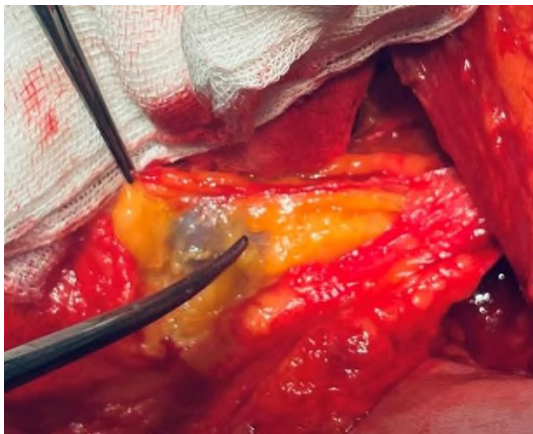


Fig. 3. Excision of a lymph node painted with Patent Blue dye.



Fig. 4. Sentinel lymph node stained with ICG dye 15 minutes after injection.

After dissecting stained lymph nodes, a pathohistological examination was performed during the operation. In addition, sentinel lymph nodes were also examined with the help of immunohistochemical analysis if a metastatic lesion was suspected. In the absence of signs of metastatic cells in the lymph nodes, only two sentinel lymph nodes were dissected, and axillary lymph node dissection was not performed. The advantages of this technology include the simplicity of this method and the absence of radiation exposure.

Patients who underwent mastectomy with biopsy of sentinel lymph nodes mostly had a clinical diagnosis of T2-T3N0M0 breast cancer. All patients with lesions of the sentinel lymph nodes in the postoperative period were given adjuvant therapy according to the ESMO/NCCN recommendations [3, 7, 8].

Results of the study and their discussion. Even though screening programs for detecting early stages of breast cancer are increasingly being implemented in practice, the treatment of breast cancer is still associated with mandatory surgical intervention. Combined and complex approaches of systemic therapy contribute to a significant reduction in radical operations in the form of mastectomies and an increase in the number of organ-sparing operations (by detecting sentinel lymph nodes, which are a predictor of the stage of the disease), which contributes to reducing the volume of surgical intervention, as well as improving the quality of the patient's future life.

In 57 % of patients (both groups combined), the sentinel lymph nodes were unaffected by metastases. Therefore, subsequent lymph node dissection was not performed. The number of cases of metastatic lymph nodes was 43 %. No case of an allergic reaction after administering dyes was registered during this study. A greenish coloration of the patient's skin was noted as a side effect after using dyes, observed in such women for three to four weeks.

The time of observation of the patients it was ranged from 60 to 180 months. After applying the treatment method, we proposed (removal of only metastatically affected sentinel lymph nodes without lymph node dissection), the number of local and distant recurrences in both groups is presented in Tables 1 and 2. Thus, in the 1st group of patients, this indicator was 17 %, and in the 2nd group – 9 %.

Lymphostasis of the upper limbs from the side of the biopsy occurred in group I in 4 % of patients and group II – in 2 % of patients (Tables 1, 2). No difference in overall survival was found between the groups.

Table 1

Group I Staining of lymph nodes with Patent Blue dye

Patients groups (n = 100)	Mean number of removed LNs in one patient	Number of patients with LNs without metastases	Number of patients with LNs with metastases	Presence of lymphostasis	Recurrence is local	Recurrence is remote
T1N0M0 (n = 35)	2	26 (74.3 %)	9 (25.7 %)	1 (2.8 %)	0	1 (2.8 %)
T2N0M0 (n = 35)	3	20 (57.1 %)	15 (42.8 %)	2 (5.7 %)	1 (2.8 %)	6 (17.4 %)
T3N0M0 (n = 30)	4	8 (26.6 %)	22 (73.3 %)	1 (3.33 %)	3 (10 %)	6 (20 %)
Total		54 (54 %)	46 (46 %)	4 (4 %)	4 (4 %)	13 (13 %)

Table 2

Group II Staining of lymph nodes with ICG fluorescent dye

Patients groups (n = 100)	Mean number of removed LNs in one patient	Number of patients with LNs without metastases	Number of patients with LNs with metastases	Presence of lymphostasis	Recurrence is local	Recurrence is remote
T1N0M0 (n = 35)	2	28 (80 %)	7 (20 %)	0	0	1 (2.8 %)
T2N0M0 (n = 35)	2	22 (62.8 %)	13 (37.2 %)	1 (2.8 %)	0	4 (11.4 %)
T3N0M0 (n = 30)	3	10 (33.3 %)	20 (66.6 %)	1 (3.3 %)	1 (3.3 %)	3 (10 %)
Total		60 (60 %)	40 (40 %)	2 (2 %)	1 (1 %)	8 (8 %)

When analysing the long-term treatment results by groups of the studied patients, it was found that lymphocytosis occurs two times less often in patients of the II group (compared to the I group), and distant relapses occur 1.6 times less often. We believe that such results in women of Group II occur due to a clearer staining of sentinel lymph nodes with ICG fluorescent dye, which makes it possible to reliably detect such lymph nodes and remove them.

The use of Patent Blue and ICG dyes in intraoperative staining of lymph nodes in patients with breast cancer is now the standard for mapping sentinel lymph nodes. Data analysis from the current literature [1, 3, 6] shows that detecting sentinel lymph nodes using the fluorescent dye ICG is significantly better than the radioisotope method for detecting lymph nodes.

Identifying the affected lymph nodes is critically essential in correctly staging the disease, further planning the patient's treatment and improving the quality of life of breast cancer patients after surgical intervention. Our data confirm the need to change the approach to treating breast cancer with less need for extensive surgical treatment. The low frequency of recurrence of progression to regional lymph nodes is observed in the conducted study, as well as a reduction in the frequency of such complications as lymphedema and upper extremity disease during biopsy of sentinel lymph nodes compared to lymphadenectomy of the 1st or 2nd order.

Postmastectomy syndrome is the main complication in operated women with breast cancer. Their quality of life is reduced due to discomfort due to impaired lymph flow, which manifests in edema of the upper limb, stenosis, axillary vein occlusions, and scars. This helps limit the upper limb's functions, brachial plexitis [1, 4, 8, 15].

Such complications can be minimised by detecting sentinel lymph nodes using Patent Blue and ICG dyes [3, 12]. Detection of sentinel lymph nodes shows the path of lymph outflow from the tumour to the regional nodes [5, 10, 14]. Thus, an effective method for staging the disease and predicting and planning further treatment tactics for patients with breast cancer is to find sentinel LNs [3, 4]. In our study, the detection of sentinel lymph nodes using both dyes were high at 100 %, with a false-negative rate of 9 %. At the same time, due to the brighter staining of sentinel lymph nodes with a fluorescent dye, ICG makes it possible to detect such lymph nodes and remove them reliably. The proposed method of detecting sentinel lymph nodes can also be recommended for other oncological diseases [7, 9].

The search and isolated removal of signal lymph nodes, in contrast to axillary lymph node dissection of the I and II levels, minimises the risks of postoperative complications as much as possible, such as rough scars, violation of lymphatic outflow and venous outflow in the form of stenoses, occlusions of the inguinal and subclavian veins, brachial plexitis.

Randomized trials show that the five- and ten-year survival rate after removing only the sentinel lymph nodes was the same as after radical mastectomy with complete lymph dissection [8, 9, 11]. At the same time, the results of treatment improved significantly: the quality of life of operated patients increased,

complications such as lymphostasis and swelling of the upper extremities practically did not occur such complications as lymphostasis and edema of the upper limbs, the psychological satisfaction of patients who were able to return to a full-fledged life increased dramatically [3, 4, 15].

The results of our studies demonstrate that total axillary lymph node dissection is an outdated approach. Mastering new technologies with new approaches to staining lymph nodes becomes necessary in the practice of an oncological surgeon. Detection of sentinel lymph nodes in women with breast cancer is an informative indicator in the staging of this disease, which allows improving the algorithm for intraoperative detection of sentinel lymph nodes, limits the frequency of axillary lymph dissection and enhances the quality of life of such patients after surgery [6, 9, 12].

Conclusion

Using both dyes (Patent Blue and ICG) significantly improves the results of detecting sentinel lymph nodes in patients with breast cancer. In addition, it provides the surgeon with additional information about the patient's anatomy, allowing you to individualise the scope of surgical intervention and, thereby, reduce the percentage of complications. The proposed algorithm for detecting sentinel lymph nodes allows you to decide on limiting or expanding the scope of surgical intervention already on the operating table based on the results of an emergency histological examination. When metastatic affected inguinal (sentinel) lymph nodes are detected, the operation should be expanded with mandatory removal of the lymph nodes of the second and third order. But the use of both dyes allows, in the vast majority of cases, to ensure the absence of metastasis and to abandon traumatic operations in favour of organ-preserving operations with biopsies of sentinel lymph nodes.

The method of fluorescent lymphography with ICG dye has a particular advantage over the use of Patent Blue dye due to the brighter staining of sentinel lymph nodes, which makes it possible to recommend it for broadside implementation in clinical practice. The frequency of finding sentinel lymph nodes by intraoperative staining in breast cancer patients approaches 100 %.

Prospects for further research. Identification and targeted examination of sentinel lymph nodes in breast cancer patients is a promising modern technology that provides high efficiency and accuracy, allowing surgeons to reach a new level of medical progress, a more advanced model of complex treatment. Further research into the effectiveness of the proposed method of detecting lymph nodes affected by the metastatic process in other oncological diseases is appropriate.

References

1. Aikian A, Shynkevych V, Kaidashev I. Analysis of association between the density of infiltration in primary carcinoma of the mammary gland by tumor-associated macrophages and postoperative prognosis. The Medical and ecological problems. 2019; 23, 1–2: 3–7. doi.org/10.31718/mep.2019.23.1-2.01
2. Canavese G, Bruzzi P, Catturich A. Sentinel lymph node biopsy versus axillary dissection in node-negative early-stage breast cancer: 15-year follow-up update of a randomized clinical trial. Ann Surg Oncol. 2016; 23: 2494–2500. https://doi.org/10.1245/s10434-016-5177-4
3. Chen J. Regional lymph node metastasis and axillary surgery of microinvasive breast cancer: A population-based study. Diagnostics. 2022; 12, 5: 1049. https://doi.org/10.3390/diagnostics12051049
4. Fan B. Role of sentinel lymph node biopsy in microinvasive breast cancer. Ann. Surg. Oncol. 2020; 27, 11: 4468–4473. https://doi.org/10.1245/s10434-020-08606-3
5. Kim M, Kim HJ, Chung YR, Kang E, Kim EK, Kim SH et al. Microinvasive carcinoma versus ductal carcinoma in situ: A comparison of clinicopathological features and clinical outcomes. J. Breast Cancer. 2018; 21, 2: 197–205. https://doi.org/10.4048/jbc.2018.21.2.197
6. Kuerer HM. DCIS margins and breast conservation: MD Anderson Cancer Center multidisciplinary practice guidelines and outcomes. J. Cancer. 2017; 1, 8, 14: 2653–2662. https://doi.org/10.7150/jca.20871
7. Li Y, Zhang S, Wei X, Zhang J. The clinical features and management of women with ductal carcinoma in situ with microinvasion: A retrospective Cohort study. Int J Surg. 2015; 19: 91–94. https://doi.org/10.1016/j.ijssu.2015.05.013
8. Lillemoe TJ, Tsai ML, Swenson KK. Clinicopathologic analysis of a large series of microinvasive breast cancers. Breast J. 2018; 24, 574–579. doi: 10.1111/tbj.13001.
9. Magnoni F. Sentinel lymph node biopsy in microinvasive ductal carcinoma in situ. Br. J. Surg. 2019; 106, 4: 375–383. https://doi.org/10.1002/bjs.11079
10. Niu H.-F. Is adjuvant chemotherapy necessary for patients with microinvasive breast cancer after surgery? Cancer Biol. Med. 2016; 13, 1: 142–149. https://doi.org/10.28092/j.issn.2095-3941.2015.0093
11. Pu T. Long term prognosis of ductal carcinoma in situ with microinvasion: A retrospective cohort study. Int J Clin Exp Pathol. 2018; 11, 5: 2665–2674.
12. Si J. Multiple microinvasion foci in ductal carcinoma in situ is associated with an increased risk of recurrence and worse survival outcome. Front. Oncol. 2020; 10: 2735. https://doi.org/10.3389/fonc.2020.607502
13. Zhang H. Significance of HER2 in microinvasive breast carcinoma: A single academic institution experience. Am. J. Clin. Pathol. 2021; 156, 1: 155–165. https://doi.org/10.1093/ajcp/aqaa222
14. Zhang G. Comparison of breast ductal carcinoma in situ and ductal carcinoma in situ with microinvasion, and analysis of axillary lymph node metastasis. Medicine. 2020; 99, 52: e23593. https://doi.org/10.1097/MD.00000000000023593
15. Zheng J, Yu J, Zhou T. Clinical characteristics of breast ductal carcinoma in situ with microinvasion: A narrative review. J. Int. Med. Res. 2020; 48, 11, 300060520969304. https://doi.org/10.1177/0300060520969304

Стаття надійшла 27.02.2022 р.