

- III.
5. Often sick children / Albitsky V.Yu., Baranov A.A., Kamaev I.A [et al.] - N. Novgorod: NGMA, 2003.
6. Mfunu Endam L. Association of IL1A, IL1B, and TNF gene polymorphisms with chronic rhinosinusitis with and without nasal polyposis: A replication study / L.Mfunu Endam, C.Cormier, Y.Bossй, A.Filali-Mouhim, M.Desrosiers // Arch Otolaryngol Head Neck Surg. — 2010. — Vol.136 (2). — P.187-192.
7. RSV respiratory infection in children under 5 y.o.—dynamics of the immune response Th1/Th2 and IgE / W.Gut, K.Pancer, E.Abramczuk [et al.] // Przegl. Epidemiol. — 2013. — Vol.67 (1). — P.17-22
8. Tewfik M.A Genetics of chronic rhinosinusitis: a primer / M.A.Tewfik, Y.Bossй, H.Al-Shemari, M.Desrosiers // J.Otolaryngol.Head.Neck.Surg. — 2010. — Vol.39, №1. — P.62-68.

*Впервые поступила в редакцию 01.08.2019 г.
Рекомендована к печати на заседании редакционной коллегии после рецензирования*

УДК 616.12 - 008.313-07-08
DOI <http://dx.doi.org/10.5281/zenodo.3465310>

THE COMPLEX FRACTIONATED ACTIVITY ZONES AS PREDICTORS OF ATRIAL FIBRILLATION RELAPSE IN PATIENTS WITH PERMANENT ATRIAL FIBRILLATION

Goriachyi A.V.

Odessa National medical university

ЗОНИ КОМПЛЕКСНОЇ ФРАГМЕНТОВАНОЇ АКТИВНОСТІ ЯК ПРЕДИКТОРИ РЕЦИДИВУ ФІБРИЛЯЦІЇ ПЕРЕДСЕРДЬ У ПАЦІЄНТІВ З ПОСТІЙНОЮ ФОРМОЮ ФІБРИЛЯЦІЄЮ ПЕРЕДСЕРДЬ

Горячий О.В.

Одеський Національний медичний університет

ЗОНЫ КОМПЛЕКСНОЙ ФРАГМЕНТИРОВАННОЙ АКТИВНОСТИ КАК ПРЕДИКТОРЫ РЕЦИДИВА ФИБРИЛЛЯЦИИ ПРЕДСЕРДИЙ У ПАЦИЕНТОВ С ПОСТОЯННОЙ ФОРМОЙ ФИБРИЛЛЯЦИИ ПРЕДСЕРДИЙ

Горячий А.В.

Одесский Национальный медицинский университет

Summary/Резюме

Scientific evidence suggests that complex fractionated activity zones help maintain atrial fibrillation. However, the electrophysiological characteristics of the left atrial myocardium that is responsible for the occurrence of complex fractionated activity are still not fully understood. We studied the electrophysiological characteristics of complex fractionated activity zones in patients with a permanent form of atrial fibrillation on the background of an attack and on a sinus rhythm.

Key words: *atrial fibrillation, complex fractionated activity.*

Багато авторів свідчать про те, що зони комплексної фрагментованої активності сприяють підтримці фібриляції передсердь. Однак, електрофізіологічні характеристики міокарда лівого передсердя відповідального за виникнення комплексної фрагментованої активності досі до кінця не вивчені.

Ключові слова: *фібриляція передсердь, комплексна фрагментована активність.*

Многие авторы говорят о том, что зоны комплексной фрагментированной активности способствуют поддержанию фибрилляции предсердий. Однако, электрофизиологические характеристики миокарда левого предсердия ответственного за возникновение комплексной фрагментированной активности до сих пор до конца не изучены.

Ключевые слова: *фибрилляция предсердий, комплексная фрагментированная активность.*

In recent years, catheter ablation of atrial sites where the so-called complex fractionated activity (CFA) zones of the atria have been widely used in the treatment of atrial fibrillation (AF) [1-3]. It is described that CFA zones induce activation of the left atrium (LA) and shorten the atrial refractory period on the one hand, and on the other hand, a complex fractionated atrial electrogram slows down and leads to inhomogeneous distribution of excitation during AF. As a result, CFA plays a significant role in maintaining AF. However, the electrophysiological characteristics of the LA myocardium responsible for the occurrence of CFA are still not fully understood.

Objective: to study the electrophysiological characteristics of complex fractionated activity zones in patients with a permanent form of atrial fibrillation on the background of an attack and sinus rhythm.

Materials and methods

The study involved 20 patients with premanent AF (8 women and 12 men), the average age of which was 61 ± 9.2 years. The duration of the arrhythmological history ranged from 1 to 15 years, an average of 8 ± 3 years. The duration of the last episode of AF is 13.9 ± 3 months. The use of combinations of antiarrhythmic drugs of I, III classes without a positive

effect.

An intracardiac electrophysiological mapping of the drug was performed using the software of the electroanatomical mapping system Ensite NavX (St. Jude, USA). Against the background of AF, the anatomical localization and electrophysiological characteristics of CFA zones were determined. In order to restore sinus rhythm (SR), transthoracic electropulse therapy (EPT) was performed. According to our methodology, the LA was divided into 24 segments and the main electrophysiological parameters were measured at the sinus rhythm: amplitude, width of the electrogram, conduction velocity, premature atrial contraction (PAC) with a long (L) and short (S) adhesion interval that did not cause AF and very short clutch interval (VSCI) causing AF. These parameters were compared in the zone with CFA and without it. After repeated induction of AF, patients underwent catheter isolation of the mouths of the pulmonary veins with linear ablation and modification of CFA zones.

Results

CFA zones were recorded in all patients in the field of collectors of the left pulmonary veins (LV) -82%, right LV-79%, coronary sinus (CS) -96%, and LP ear -85% (Figure 1.).

With programmed stimulation of the

coronary sinus.

The clutch interval D-, K- and OK- were 291 ± 87 , 206 ± 47 and 175 ± 33 ms. During the sinus rhythm, the amplitudes in the areas with CFA were significantly higher than in the areas without CFA, D-, K-, and OK-PPS ($2.0 \pm 1.3 - 0.5 \pm 0.6$ mV, $p < 0.01$; $1.3 \pm 1.2 - 0.3 \pm 0.3$ mV, $p < 0.001$; $0.7 \pm 0.7 - 0.2 \pm 0.2$ mV, $p < 0.001$). Following the shortening of the adhesion interval in areas with CFA and without, a decrease in the signal amplitude was noted. The width of the complex in the zone with CFA did not differ from the zone without CFA with D-PPS ($65.9 \pm 9.2 - 63.8 \pm 12.6$ ms, $p = \text{NS}$; $79.6 \pm 17.2 - 69.6 \pm 12.4$ ms, $p = \text{NS}$), however, during K- and OK-PPS the width of the complex in the CFA zone was significantly wider than in the non-CFA non-zone ($95.9 \pm 18.8 - 81.6 \pm 17.1$ ms $p < 0.05$; $103.5 \pm 86.4 - 86.4 \pm 21.0$ mV, $p < 0.003$). The speed of conducting D-, K-, and OK-PPS during the sinus rhythm in the CFA zone was significantly slower than in the zone without CFA ($1.3 \pm 0.4 - 2.1 \pm 1.0$ m / s, $p = 0.001$; $1.3 \pm 0.4 - 2.3 \pm 1.2$ m / s, $p = 0.005$; $1.1 \pm 0.5 - 2.0 \pm 1.1$ m / s, $p = 0.002$; and $0.9 \pm 0.5 - 1.8 \pm 0.8$ m / s, $p < 0.001$).

Conclusions

CFA zones were located in areas with high-amplitude activity, slow, heterogeneous conduct, and were directly related to premature activation of the drug. Thus, a structural change in tissue is not the only mechanism underlying the genesis of CFA, but the non-homogeneity of the conduction created in high-amplitude regions can also contribute to the maintenance of AF.

References

1. Claire A Martin, James P Curtain, Parag R Gajendragadkar, David A Begley, Simon P Fynn, Andrew A Grace, Patrick M Heck, Munmohan S Virdee, and Sharad Agarwal.

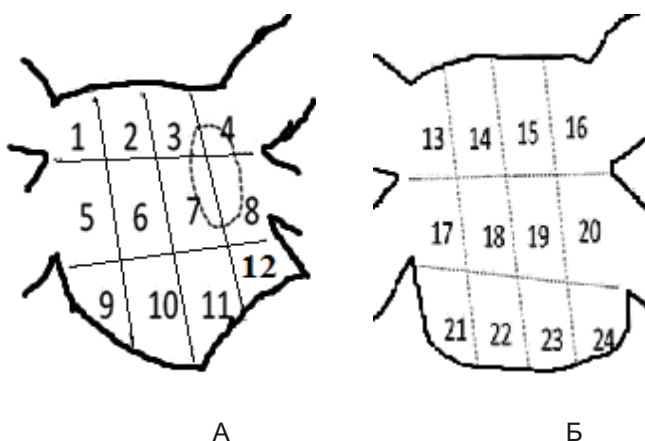


Fig. 1 Anterior (A) and posterior (B) surface of the left atrium.

Ablation of Complex Fractionated Electrograms Improves Outcome in Persistent Atrial Fibrillation of Over 2 Year's Duration/ J Atr Fibrillation, - 2018 Feb; 10(5): 1607.

2. Kong Melissa H, Piccini Jonathan P, Bahnson Tristram D. Efficacy of adjunctive ablation of complex fractionated atrial electrograms and pulmonary vein isolation for the treatment of atrial fibrillation: a meta-analysis of randomized controlled trials. Europace. 2011 Feb;13 (2):193–204.
3. Wong Kelvin C K, Paisey John R, Sopher Mark, Balasubramaniam Richard, Jones Michael, Qureshi Norman, Hayes Chris R, Ginks Matthew R, Rajappan Kim, Bashir Yaver, Betts Timothy R. No Benefit of Complex Fractionated Atrial Electrogram Ablation in Addition to Circumferential Pulmonary Vein Ablation and Linear Ablation: Benefit of Complex Ablation Study. Circ Arrhythm Electrophysiol. 2015 Dec;8 (6):1316–24
4. Nademanee K, Oketani N. The role of complex fractionated atrial electrograms in atrial fibrillation ablation moving to the beat of a different drum// J Am Coll Cardiol.- 2009.- Vol.-53.P-790–791
5. Oral H, Chugh A, Yoshida K, Sarrazin JF, Kuhne M, Crawford T, et al A randomized assessment of the incremental role of ablation of complex fractionated atrial electrograms after pulmonary vein isolation for long-lasting persistent atrial fibrillation.// J Am Coll Cardiol.- 2009.-Vol.-53:782–789

*Впервые поступила в редакцию 07.08.2019 г.
Рекомендована к печати на заседании редакционной коллегии после рецензирования*